

Canine Elbow Dysplasia and Its Inheritance

By Jerold S Bell, DVM, Tufts University School of Veterinary Medicine

(This article originally appeared in the "Healthy Dog" section of the April, 2003 *AKC Gazette*)

Elbow dysplasia is a painful condition that can cause lameness and arthritis. Affected dogs typically show signs of this condition between 4 and 10 months of age. The most common clinical sign is intermittent or persistent front-leg lameness that gets worse with exercise. The elbow can be swollen, have reduced range of motion, and be painful to move. There can be concurrent muscle atrophy in the leg.

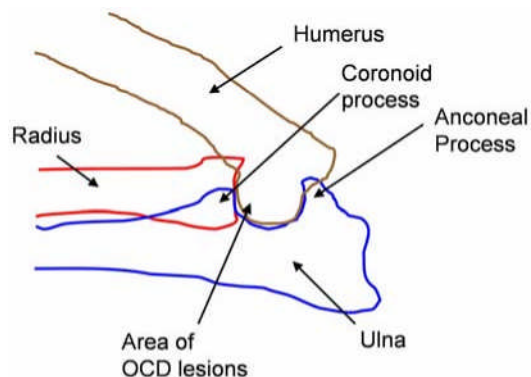
First, some background. The elbow is formed by the coming together of the upper arm bone (the humerus) and the two parallel lower arm bones (the radius and ulna). These bones must grow and develop in unison to maintain a tight-fitting and smoothly moving elbow joint.

The disorder known as elbow dysplasia encompasses a collection of problems with the elbow joint, including ununited anconeal process (UAP), fragmented coronoid process (FCP), and osteochondritis dessicans (OCD) of the end of the humerus.

Many researchers believe that all three of these problems can be caused by unsynchronized growth of these bones, causing misalignment of the elbow joint. This can create incongruity between the radius and ulna (UAP), abnormal wear and tear between the humerus and radius (FCP), or erosion of cartilage between the humerus and ulna (OCD).

The anconeal process begins to unite with the rest of the ulna when the dog is about 3 months of age, and is completely fused by 4 to 5 months of age. An ununited anconeal process is diagnosed by a failure to unite by 5 months of age. Previously, it was thought that the problem with UAP was in the connection of the process to the ulna. However, it is now believed that the problem is a discrepancy in growth between the radius and ulna. The longer-growing radius pushes the humerus into the anconeal process, preventing its union. Surgeons are now successfully treating UAP by cutting the ulna bone, which relieves the pressure from the radius and restores congruity to the elbow joint. Even if the anconeal process does not unite, pain and the progression of degenerative joint disease are usually halted.

Due to the overlap of bones on a radiograph, a fragmented coronoid process is difficult to visualize. It is most often diagnosed based on secondary degenerative joint disease and the formation of new bone proliferation (osteophytes) in the region.



FCP can be inherited differently in

different breeds. There is an even sex ratio in the Bernese Mountain Dog, however, 75 percent of affected Labrador Retrievers are male.

Care and Screening

Early diagnosis of elbow dysplasia allows the initiation of proper medical or surgical treatment, and can minimize the progression of arthritis. Depending on the severity of the lesions, treatment can involve surgery, or conservative therapy involving rest, weight control, nonsteroidal anti-inflammatory medication, and chondroprotective agents (glucosamine and chondroitin). Steroid medication (prednisone) should be avoided, as it can promote further cartilage damage.

Genetic studies show that elbow dysplasia is a polygenic disorder, and that FCP, OCD, and UAP are independently inherited traits. It is a moderately inherited disorder, with less environmental influence than hip dysplasia.

The elbow dysplasia registry of the Orthopedic Foundation for Animals (OFA) is based on an extreme flexed lateral radiograph of the elbows. Besides a UAP, the most sensitive radiographic sign of elbow dysplasia is arthritis. Due to this finding, the OFA will not certify an elbow as normal before 2 years of age. Owners should have their elbows radiographed at the same time as their hip radiograph.

The OFA will rate each elbow as normal, or as dysplastic Grade I, Grade II, or III. The grades have to do with the severity of dysplasia but not the specific lesion causing the diagnosis. Breeders should pay particular attention to the location of the lesion in dysplastic elbows to select against it in their breeding program.

The Numbers

Across all breeds, 9.3 percent of all dogs evaluated for elbow dysplasia are dysplastic (see charts). Of affected dogs, 78.5 percent were Grade I, 15.6 percent were Grade II, and 5.9 percent were Grade III. Dogs with Grade I dysplasia often have no pain or clinical signs associated with the disorder. However, whenever a dog is suffering from Grade II or III elbow dysplasia, first-degree relatives (a parent, full sibling, aunt, or uncle) are almost always found with Grade I elbow dysplasia. Diligent screening of breeding stock and their siblings is required to avoid or decrease the prevalence of elbow dysplasia.

An examination of OFA data on 13,151 dogs whose parents both had elbow evaluations showed that the percentage of offspring with elbow dysplasia more than doubled (compared to dogs whose parents both had normal elbows) if one parent had any grade of dysplasia, and more than tripled if both parents were affected.

For the breeding management of elbow dysplasia, select normal dogs who have normal parents, littermates, and littermates of parents. Many breed clubs have made this selection easier by listing elbow screening results at the Canine Health Information Center (CHIC) at www.caninehealthinfo.org.

* * * * *

OFA Elbow Statistics (In breeds with > 100 evaluations)
Breeds with the highest percentage of Elbow Dysplasia

Chow Chow	44.7%
Rottweiler	41.8%
Bernese Mountain Dog	30.7%
Chinese Shar-Pei	27.7%
Newfoundland	27.2%
German Shepherd Dog	20.2%
Bulldog	19.1%
Bloodhound	16.4%
English Setter	16.2%
Am. Staffordshire Terrier	16.0%

Breeds with the lowest percentage of Elbow Dysplasia

Border Collie	0.4%
Briard	0.6%
Bearded Collie	0.8%
Curly-Coated Retriever	0.9%
Boxer	0.9%
Shiba Inu	1.0%
Flat-Coated Retriever	1.0%
German Shorthaired Pointer	1.3%
Weimaraner	1.4%
Portuguese Water Dog	1.4%